

# Terms, definitions and measurements to describe the sonographic features of adnexal tumors: a consensus opinion from the International Ovarian Tumor Analysis (IOTA) group

D. TIMMERMAN, L. VALENTIN\*, T. H. BOURNE†, W. P. COLLINS‡, H. VERRELST§ and I. VERGOTE

Department of Obstetrics and Gynaecology, University Hospitals KU Leuven, Leuven, Belgium, \*Department of Obstetrics and Gynaecology, University Hospital, Malmö, Sweden, †Department of Obstetrics and Gynaecology, St. George's Hospital Medical School, University of London, London, UK, ‡King's College, University of London, UK and §Department of Electrical Engineering, ESAT-SISTA, Katholieke Universiteit Leuven, Belgium

**KEYWORDS:** Ultrasonography, Color Doppler imaging, Ovary, Definitions, Standardization

## INTRODUCTION

The lack of standardized terms and procedures to derive categorical and continuous variables in gynecological sonography is a general cause of concern<sup>1</sup>. The extent of the problem became more apparent to us during the planning stage of an international, multicenter study to characterize adnexal masses by ultrasonographic criteria using the histologic and surgical classification of each mass as the reference procedure. A detailed review of the literature had revealed considerable variation in the diagnostic accuracy of test procedures<sup>2</sup>. There had also been much discussion and more recently a report that the use of diagnostic algorithms derived from the retrospective analysis of data in a particular center<sup>3–5</sup> does not produce such good results when used prospectively in another center<sup>6</sup>. The possibility arose that both findings might be explained, at least in part, by differences in the interpretation and use of terms and definitions of the diagnostic end-points. Consequently, a new initiative was started to address the problem, which of necessity involved the participation of researchers from different centers; the participants comprise the International Ovarian Tumor Analysis (IOTA) group (see list below). The steering committee for the study held special meetings to discuss the problems of standardization and to formulate terms and procedures to derive morphologic end-points by B-mode imaging and end-points of vascularity and blood flow by color Doppler imaging. The recommendations of the steering committee were distributed to each participating center and subsequently refined after meeting with the principal investigators. The following consensus opinion is being used in the multicenter study and in our routine

practices. We hope that the outcome of our deliberations will stimulate further debate, which will eventually lead to internationally agreed terms and definitions within our speciality.

## DEFINITIONS

### Lesion

An adnexal *lesion* is the part of an ovary or an adnexal mass that is judged from an assessment of ultrasound images to be inconsistent with normal physiologic function. This situation can arise from the presence of a persistent unilocular cyst, surrounded by normal looking ovarian stroma containing some follicles. In this case the whole ovary containing the cyst is the 'ovary', whereas the unilocular cyst is the 'lesion'. The size of both structures is measured independently, and the cyst is described as being 'unilocular' and not 'unilocular-solid' (see below under 'classification'). In other cases the lesion is separate from the ovaries (e.g. hydrosalpinx). Again, the size of both ovaries and the lesion are measured separately. In some cases normal ovarian stroma is not visible; the lesion and the ovary are undistinguishable, and consequently the size of the lesion and the ovary will be the same.

### Morphological features

A *septum* is defined as a thin strand of tissue running across the cyst cavity from one internal surface to the contralateral side.

An *incomplete septum* (as seen in hydrosalpinges) is defined as a thin strand of tissue running across the cyst

Correspondence: Dirk Timmerman, Department of Obstetrics and Gynaecology, University Hospitals Leuven, Herestraat 49, B-3000 Leuven, Belgium.

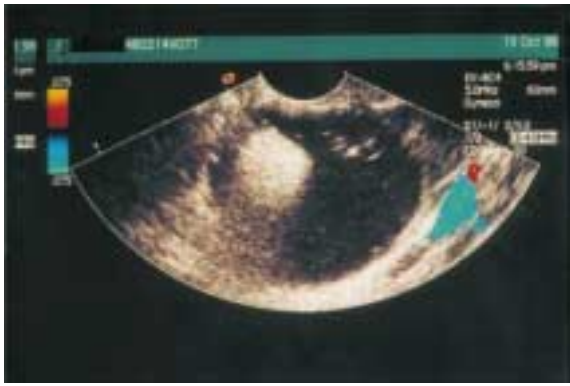

Figure 1 Hyper-reflective and avascular area in the center of a benign dermoid cyst.

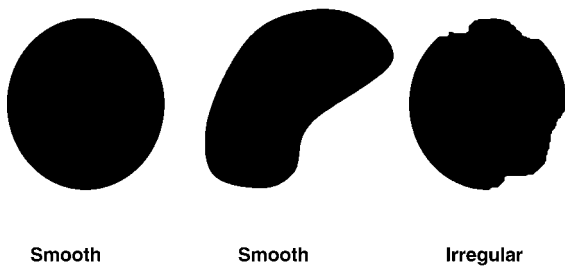


Figure 2 The internal wall of the cyst is noted as being smooth or irregular.

cavity from one internal surface to the contralateral side, but which is not complete in some scanning planes. Its presence is noted. If a cyst has only incomplete septa and no real septa, it is recorded as unilocular, despite the fact that in certain sections the cyst appears to be multilocular (see below under ‘classification’).

*Solid* means exhibiting high echogenicity suggesting the presence of tissue (e.g. myometrium, the ovarian stroma, myomas, fibromas). In adnexal tumors diffuse wall thickening, normal ovarian stroma, and regular septa are not regarded as ‘solid’ tissue. Methods to distinguish between blood clots and the presence of solid tissue involve pushing

the transducer gently towards the structure and looking for internal movement, and the use of color Doppler imaging. The presence of flow (with the appropriate settings) is diagnostic for solid tissue. The absence of flow is not informative. In cases of doubt whether a blood clot or a solid area is present, then the lesion is classified as solid.

*Solid papillary projections* are defined as any solid projections into the cyst cavity from the cyst wall with a height greater than or equal to 3 mm. The worse case should be reported if there is uncertainty whether a solid papillary projection or an incomplete septum is present. For example, excrescences associated with the ‘cogwheel’ sign and the ‘beads-on-a-string’ sign (as seen in hydrosalpinges)<sup>7</sup> should be classified as papillary projections if their height is greater than or equal to 3 mm. The hyper-reflective and avascular area in the center of a dermoid cyst<sup>8</sup> should not be classified as a solid papillary projection (Figure 1). Similarly, ‘sludge’ on the internal walls of endometriotic cysts is not regarded as a papillary projection. In these cases the internal walls are called ‘irregular’. Solid papillary projections are described as being ‘smooth’ or ‘irregular’ (e.g. cauliflower-like).

The internal wall is described as being ‘smooth’ or ‘irregular’ (see Figure 2). If there is a solid papillary projection, then the wall is irregular by definition. The external wall of a cyst is not taken into account. In cases of solid tumors the description of the internal wall as being smooth or irregular is usually not applicable but the outline of the tumor is described as smooth or irregular. If there is any irregularity in either the inner wall of any cyst or in the outer wall of a solid tumor or on the surface of a solid component, the lesion is described as ‘irregular’.

The dominant feature of the *cystic contents* is described as anechoic (black), low-level echogenic (i.e. homogeneous low-level echogenic as seen in mucinous tumors or an appearance similar to amniotic fluid), ‘ground glass’ appearance (homogeneously dispersed echogenic cystic contents, as often seen in endometriotic cysts), hemorrhagic (with internal thread-like structures, representing fibrin strands; in hemorrhagic cysts it is possible to describe the echogenicity as star-shaped, cobweb-like or




Figure 3 The dominant feature of the cystic contents in complete septum, e.g. in hydrosalpinx.

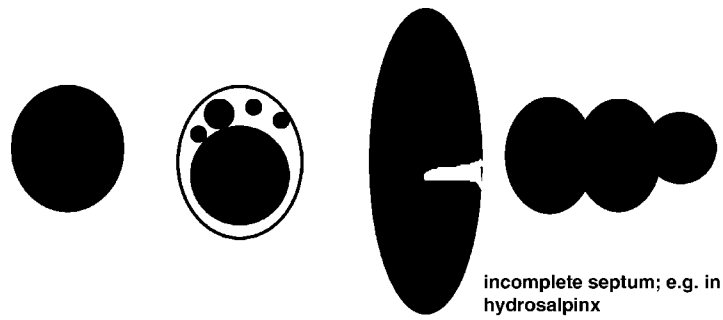


Figure 4 Examples of different kinds of unilocular cysts. A unilocular cyst is a cyst without septa and without solid parts or papillary structures.

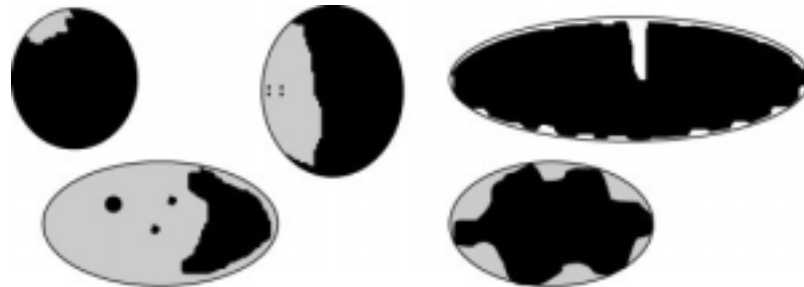


Figure 5 Examples of different kinds of unilocular-solid cysts. A unilocular-solid cyst is a unilocular cyst with a measurable solid component or at least one papillary structure. If the solid part contains very small cysts the mass might be unilocular-solid.

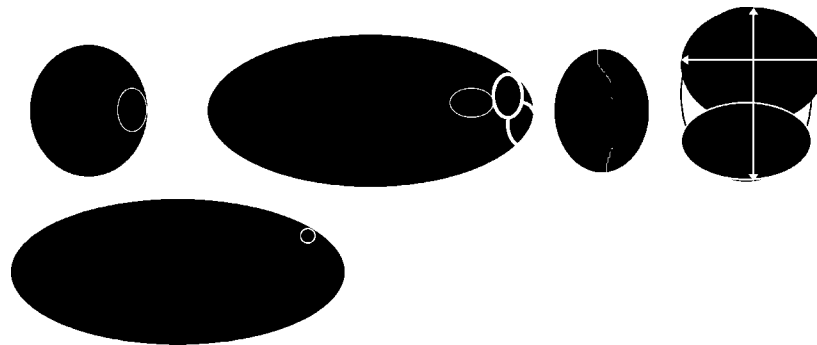


Figure 6 Examples of different kinds of multilocular cysts. A multilocular cyst is a cyst with at least one septum but no measurable solid components or papillary projections. The 'lesion' is measured in the planes indicated by the arrows.



Figure 7 Examples of different kinds of multilocular-solid cysts. A multilocular-solid cyst is a multilocular cyst with a measurable solid component or at least one papillary structure (solid tumor with an irregular cyst wall).




Figure 8 Examples of different kinds of solid tumors. A solid tumor is a tumor where the solid components comprise 80% or more of the tumor when assessed in a two-dimensional section. A solid tumor may contain papillary projections protruding into internal small cysts.

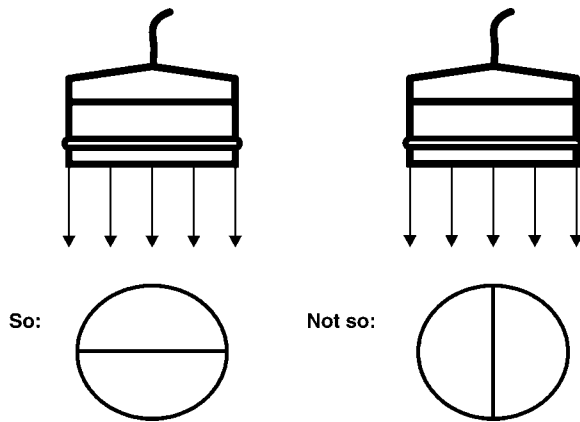


Figure 9 It is preferable to measure a septum which is perpendicular to the ultrasound beam.

jelly-like), or mixed echogenic (as often seen in teratomas) (see Figure 3). In solid tumors, the dominant feature of any cystic contents is only described if it can be assessed.

The presence of *acoustic shadows*, defined as loss of acoustic echo behind a sound-absorbing structure, is noted.

*Ascites* is defined as fluid outside the pouch of Douglas and is recorded as being present or absent.

All lesions are *classified qualitatively* into one of six categories:

- *unilocular cyst* (Figure 4 – a unilocular cyst without septa and without solid parts or papillary structures). Normal ovarian stroma is not regarded as a ‘solid’ part of the tumor (e.g. a peritoneal cyst containing a normal ovary is classified as unilocular and not unilocular-solid).

- *unilocular-solid cyst* (Figure 5 – a unilocular cyst with a measurable solid component or at least one papillary structure). This category may include pyo- or hydrosalpinges with the so-called ‘beads-on-a-string’ or ‘cogwheel’ appearance<sup>3</sup> if their height is greater than or equal to 3 mm. If a

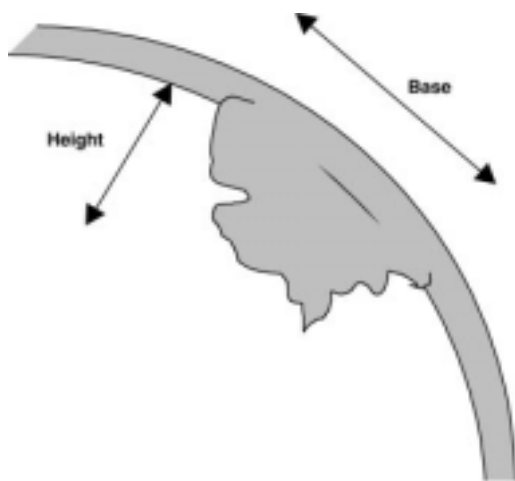


Figure 10 Solid papillary projections are defined as any solid projections into the cyst cavity from the cyst wall greater than or equal to 3 mm in height. The largest papillary projection is measured in three directions: height, base, and base.

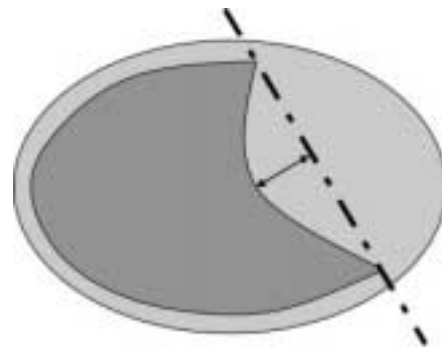


Figure 11 Schematic drawing of the imaginary line from which to measure a papillary projection.

unilocular cyst is present with a solid part containing only very small cysts, the mass might be unilocular-solid.

- *multilocular cyst* (Figure 6 – a cyst with at least one septum but no measurable solid components or papillary projections);

- *multilocular-solid cyst* (Figure 7 – a multilocular cyst with a measurable solid component or at least one papillary projection);

- *solid tumor* (Figure 8 – a tumor where the solid components comprise 80% or more of the tumor when assessed in a two-dimensional section). A solid tumor may contain papillary projections protruding into the small cysts of the solid tumor.

- *not classifiable* because of poor visualization (e.g. strong acoustic shadowing due to calcifications or as seen in certain dermoids<sup>9</sup>).

### Measurements and quantitative assessment of morphology

#### Lesion.

The size of both ovaries and the lesion(s) are measured as the largest three diameters (in mm) in two perpendicular planes.

#### Septum.

The thickness of the thickest septum is measured where it appears to be at its widest (other than at its interface at the

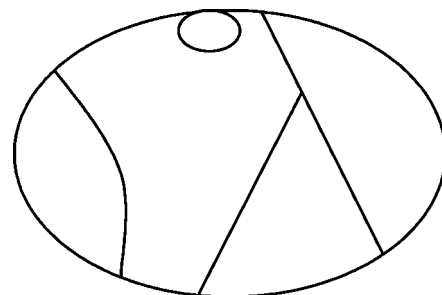


Figure 12 Schematic drawing of a multilocular cyst containing five locules and four septa. The number of locules in the whole volume of the tumor is counted.

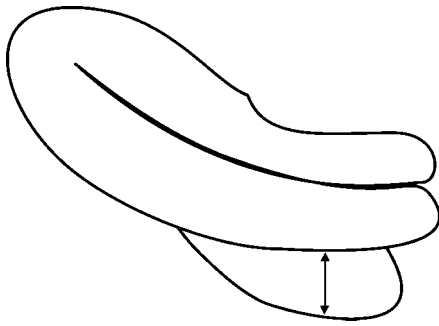


Figure 13 Fluid in the pouch of Douglas is measured in a sagittal plane. The largest anteroposterior diameter is given.

internal surface of the cyst wall). Because the axial resolution of most ultrasound equipment is superior to the lateral resolution, it is preferable to measure a septum which is perpendicular to the ultrasound beam (see Figure 9).

#### Papillary projection.

The largest projection is measured in two perpendicular planes: height, base, and base as illustrated in Figure 10. The number of separate papillary projections (1/2/3/more) and whether blood flow can be detected in any of these are recorded. In some cases it is difficult to judge whether a papillary projection is present and from which base the projection should be measured. In these cases it may be helpful to use an imaginary line as illustrated in Figure 11.

The number of locules are counted<sup>1-10, > 10</sup> (i.e. the true number of locules, as assessed in the whole volume of the tumor) (Figure 12).

In cystic-solid tumors the *largest solid component* is measured separately (three diameters in two perpendicular planes). In some cases, a solid papillary projection is the largest solid component, and thus the papillary projection is recorded and measured *both* as a papillary projection and as solid component.

The amount of *fluid* in the pouch of Douglas is measured in a sagittal plane and the largest anteroposterior diameter is recorded in mm (Figure 13).

#### Vascular features

The entire tumor should be examined by color Doppler imaging. For tumors with several sampled areas the set of results with the highest time-averaged maximum velocity (TAMXV)<sup>3-10</sup> and the corresponding values for the pulsatility index (PI), resistance index (RI), and peak systolic velocity (PSV) are selected. If a subjective semiquantitative assessment of flow is made, the following terms can be used to describe the amount of blood flow (area and color scale) within the septa, cyst walls, or solid tumor areas: a score of 1 is given when no blood flow can be found in the lesion; a score of 2 is given when only minimal flow can be detected; a score of 3 is given when moderate flow is present, and a score of 4 is given when the adnexal mass appears highly vascular with marked blood

flow<sup>5</sup>. This color score only refers to the color Doppler image and not to the Doppler shift spectrum. It is only given once (for the tumor as a whole).

## DISCUSSION

These terms, definitions and qualitative and quantitative end-points to describe the ultrasonic features of adnexal tumors are being used in the protocol for our research study with specific objectives. In routine clinical practice it is probably not essential to record all of the end-points in individual patients. Conversely, some important indices of malignancy might be absent from this list, and more will undoubtedly be revealed by technical advances in gynecological ultrasonography. New research studies to develop algorithms for the classification of adnexal masses can only be enhanced by the continuous re-assessment of the terms, definitions and end-point measures.

## ACKNOWLEDGMENTS

The IOTA study is supported by a research grant from the 'Interdisciplinair Onderzoekprogramma' (IDO/99/003) provided by the Onderzoeksraad Katholieke Universiteit Leuven, Leuven, Belgium.

## ADDENDUM

### IOTA steering committee

Dirk Timmerman, Leuven, BELGIUM. Thomas H. Bourne, London, UK. William P. Collins, London, UK. Lil Valentin, Malmö, SWEDEN. Sabine Van Huffel, Leuven, BELGIUM. Herman Verrelst, Leuven, BELGIUM. Ignace Vergote, Leuven, BELGIUM.

### IOTA principal investigators

Jean-Pierre Bernard, Maurepas, FRANCE. Thomas H. Bourne, London, UK. Bruno Cacciatore, Helsinki, FINLAND. Enrico Ferrazzi, Milan, ITALY. Arthur C. Fleischer, Nashville, USA. Steven R. Goldstein, New York, USA. Seth Granberg, Göteborg, SWEDEN. Berit Gull, Göteborg, SWEDEN. Davor Jurkovic, London, UK. Fabrice Lécuru, Paris, FRANCE. Ulrike Metzger, Paris, FRANCE. Anna Parsons, Tampa, FL, USA. Dario Paladini, Naples, ITALY. Peter Schwärzler, Innsbruck, AUSTRIA. Aydin Tekay, Oulu, FINLAND. Antonia Testa, Roma, ITALY. Dirk Timmerman, Leuven, BELGIUM. Lil Valentin, Malmö, SWEDEN. Sabine Van Huffel, Leuven, BELGIUM. Dominique Van Schoubroeck, Leuven, BELGIUM. Ignace Vergote, Leuven, BELGIUM. Herman Verrelst, Leuven, BELGIUM. Gerardo Zanetta, Monza, ITALY.

## REFERENCES

- 1 Timmerman D. Lack of standardization in gynecological ultrasonography (Editorial). *Ultrasound Obstet Gynecol* 2000; 16: 395-398

- 2 Timmerman D. Ultrasonography in the assessment of ovarian and tamoxifen-associated endometrial pathology. Thesis. Leuven, Belgium 1997
- 3 Tailor A, Jurkovic D, Bourne T, Collins W, Campbell S. Sonographic prediction of malignancy in adnexal masses using multivariate logistic regression analysis. *Ultrasound Obstet Gynecol* 1997; 10: 41–7
- 4 Alcazar JL, Jurado M. Using a logistic regression model to predict malignancy of adnexal masses based on menopausal status, ultrasound morphology, and color Doppler findings. *Gynecol Oncol* 1998; 69: 146–50
- 5 Timmerman D, Bourne TH, Tailor A, Collins WP, Verrelst H, Vandenberghe K, Vergote I. A comparison of methods for the pre-operative discrimination between benign and malignant adnexal masses: the development of a new logistic regression model. *Am J Obstet Gynecol* 1999; 181: 57–65
- 6 Aslam N, Banerjee S, Carr JV, Savvas M, Hooper R, Jurkovic D. Prospective evaluation of logistic regression models for the diagnosis of ovarian cancer. *Obstet Gynecol* 2000; 96: 75–80
- 7 Timor-Tritsch IE, Lerner JP, Monteagudo A, Murphy KE, Heller DS. Transvaginal sonographic markers of tubal inflammatory disease. *Ultrasound Obstet Gynecol* 1998; 12: 56–66
- 8 Cohen L, Sabbagha R. Echo patterns of benign cystic teratomas by transvaginal ultrasound. *Ultrasound Obstet Gynecol* 1993; 3: 120–3
- 9 Caspi B, Appelman Z, Rabinerson D, Elchalal U, Zalel Y, Katz Z. Pathognomonic echo patterns of benign cystic teratomas of the ovary: classification, incidence and accuracy rate of sonographic diagnosis. *Ultrasound Obstet Gynecol* 1996; 7: 275–9
- 10 Valentin L. Gray scale sonography, subjective evaluation of the color Doppler image and measurement of blood flow velocity for distinguishing benign and malignant tumors of suspected adnexal origin. *Eur J Obstet Gynecol Reprod Biol* 1997; 72: 63–7211